

# Surgical Management of Subcutaneous Abscess in Indian Rat Snakes (*Ptyas mucosa*) using Isoflurane for Anesthesia

Sanath Krishna Muliya<sup>1</sup>, Karthik Manjunath<sup>2</sup>, K.M. Srinivas Murthy<sup>3</sup>, Yashaswi Naravi<sup>4</sup>, Lingappa Ranganath<sup>5</sup> and M. Narayana Bhat<sup>6</sup>

## Abstract

Two Indian rat snakes (*Ptyas mucosa*) from Bannerghatta Biological Park were presented with localized swellings on lateral aspect of body. Thorough physical examination after physical restraint showed multiple localized, hard abscesses. These Abscesses were surgically managed using isoflurane as inhalant anesthetics. The present communication reports protocols followed during the surgical procedure and subsequent findings.

## Introduction

Indian rat snake is a colubrid found throughout south and south East Asia, from sea level to 4,000m (13,120ft). It is one of the most common snakes found throughout the country (Whitaker and Captain, 2004). Abscesses are one of the most frequent clinical entities of the captive snakes (Hoppmann and Barron, 2006). It is a localized collection of purulent material in a confined cavity formed by disintegration of tissue. Often, abscesses are triggered by traumatic injury, bite wounds, or poor environmental conditions (Klingenberg, 2011). Such abscesses were surgically managed using Isoflurane as inhalant anesthetics. Inhalation agents are commonly used for chemical restraint of reptiles (Read, 2004). As in other species, the advantages of inhalation anesthetics include superior control of depth, wide margin of safety, excellent muscle relaxation, fast recovery, and "built in" oxygen supplementation. The present communication reports protocols followed during the surgical procedure and subsequent findings.



**Fig 1. Appearance of abscess in Indian rat snakes, some with a central scar and some without any openings.**

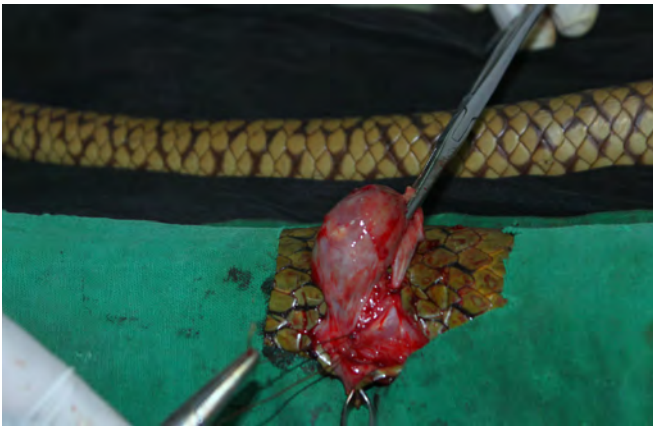

**Fig 2: The snake restrained in restraining tubes and the opposite end of the restraining tube connected to the anesthetic circuit.**

## Method

During July 2013, two captive Indian Rat snakes (*Ptyas mucosa*) from Bannerghatta Biological Park were observed to have localized swellings on lateral aspect of body. Thorough physical examination after physical restraint showed multiple localized, hard abscesses. Manipulation of snakes for the initial physical examination was

<sup>1</sup>Graduate Assistant, Department of Wildlife, <sup>2&4</sup>M.V.Sc Scholar, Department of Wildlife, <sup>3</sup> Assistant Professor, Dept. of Veterinary Surgery and Radiology, <sup>5</sup>Professor and Head, Dept. of Veterinary Surgery and Radiology, <sup>6</sup>Director, Institute of Wildlife Veterinary Research & Co-ordinator, Department of Wildlife, Veterinary College, Bangalore. Email: [1sanamuliya@yahoo.co.in](mailto:1sanamuliya@yahoo.co.in) (corresponding author).



**Fig 3. Abscess which usually appeared as capsule being removed as single mass altogether including abscess capsule.**

carried out using restraint tubes. Snake hooks were kept handy and used when ever needed. Abscesses when palpated appeared as hard and localized swellings, some with a central scar and some without any openings (Fig 1). No heat or erythema was observed in the region as in mammals. Fine needle aspiration with a sterile 24 G needle yielded no exudates.

The snakes were restrained in restraining tubes and the opposite end of the restraining tube was connected to the anesthetic circuit. Isoflurane (SOSRANE®, Metrex Pharmaceuticals, 250 ml bottle) was administered in combination with oxygen via Surgivet® small animal anesthesia machine (Smith Medical PM. Inc., Veterinary Division, Waukesha, Wisconsin, USA) of circle system with vaporizer outside the circuit (Fig. 2). Anesthesia was induced using isoflurane at the rate of 3%, delivered with oxygen (2 liters per minute) until the snake reached the surgical plane of anesthesia. The depth of anesthesia was estimated based on the tongue movements, muscle tone, tail movements, righting reflex and pain perception. At the surgical plane of anesthesia all the above reflexes were absent. The time required for induction was recorded.

After attainment of surgical plane of anesthesia, the snakes were maintained under anesthesia with 1% isoflurane. Physiological parameters are vital for monitoring anesthesia in reptiles. Respiratory rate, heart rate and cloacal temperature were recorded before anesthesia, during the surgical procedure and after complete recovery from anesthesia. The cloacal temperature was recorded using a patient monitor designed for dogs. In snakes, the normal temperature is well below 90°F which cannot be measured by the routinely used clinical thermometer. The respiratory rate was determined by direct visualization of the body wall movements whereas the heart rate was measured by direct digital palpation.

Once the snakes were positioned according to the need, site over abscess were aseptically prepared for surgery. Excessive use of alcohol swabs was avoided to check evaporative heat loss (Laboratory reptile surgery). Water bags were maintained slightly above room temperature in a warm water bath and kept ready to be used as supplemental heat source. A skin incision was made over the entire abscess. The skin was then reflected, and the abscess was removed intact. Abscess usually appeared as capsule and was removed as single mass altogether (Fig. 3). The underlying tissue was irrigated thoroughly with povidone iodine and normal saline mixture. Bleeding was stopped by ligation with absorbable suture material of suitable USP size. Skin was sutured with polyamide-monofilament suture material using horizontal mattress pattern. Surgical wound was then dressed with povidone iodine ointment, without bandaging. Post surgically, Enrofloxacin at rate of 5 mg/kg IM and Meloxicam at rate of 0.02 mg/ kg IM was administered once in 24 hours.

Post surgery, the snakes were housed in plastic containers. Newspapers were used as substrate within the boxes. A Small plastic container wrapped in newspaper was used as hide boxes within the large designer containers. Boxes were housed inside a clean room at ambient temperature with access to natural sunlight.

### Result

The first sign of anesthetic induction was cessation of tongue movements followed by loss of body and tail movements. Next there was generalized muscle relaxation of the entire body. The relaxation started from the head and proceeded towards the tail. Once the induction was complete the righting reflex and panniculus reflex was completely absent. The induction time, total time under anesthesia and recovery time are tabulated in Table 1.

**Table 1. The induction time, total time under anesthesia and recovery time under Isoflurane anesthesia**

Case No	Induction Time (Minutes)	Recovery Time (Minutes)	Total duration under anesthesia (Minutes)
1	11.17	12.06	36.55
2	6.43	11.22	32.09

No injectable anesthetics were used for pre-anesthesia of snakes in both cases. Both induction and maintenance were carried out using isoflurane as inhalant anesthesia. The procedure proved to be safe for both the snakes as well as the handler. This method was found to be reliable with induction being achieved in both cases without any difficulty. Physiological parameters recorded before induction, during surgical procedure and after recovery are tabulated in Table 2. The cloacal temperature of both

**Table 2. Physiological parameters recorded before induction, during surgical procedure and after recovery under Isoflurane anesthesia**

Parameters	Before induction of anaesthesia	During the surgical procedure	After recovery from anaesthesia
<b>Cloacal temperature (°F)</b>			
Case 1	85	81	86
Case 2	86	84	88
<b>Respiratory rate (per min.)</b>			
Case 1	5	1	5
Case 2	5	2	7
<b>Heart rate (Bpm)</b>			
Case 1	66	52	71
Case 2	75	69	73

snakes receded down by 2 to 4 °F during the surgical plane of anesthesia as compared to the temperature before induction. Even though the respiratory rate reduced to a very low level, no snakes were found to become apnoeic under the influence of isoflurane. Abscess appeared as capsule and was removed as single mass altogether. Surgical wounds healed progressively without any complications with sutures being removed by 24<sup>th</sup> day post surgery. Abscesses did not recur in both the snakes till 65<sup>th</sup> day post surgery. Snakes shed skin, one on 35<sup>th</sup> and the other on 42<sup>nd</sup> day respectively without showing any signs of dysecdysis at sutured region. Plastic containers provided safe and satisfactory housing to all the snakes used for the study. Newspapers which were used as substrate helped in keeping the box clean as they were easy to be changed frequently. They also helped in providing warmth to snakes for some extent.

### Discussion and Conclusion

Restraint of snakes using transparent restraining tubes is considered to be the safest for both the snake and the handler. This method minimizes risk to the handler and potential injury to the snake (Murphy, 1971). Once restrained, the snakes were induced with anesthesia through the same restraining tube itself. This avoided restraining of snakes for the second time and hence minimized the stress on the reptile. The same procedure was suggested by Mosley (2005), Mads (2007) and Sladky and Mans (2012). By using only inhalational anesthesia for both induction and maintenance, the usage of injectable anesthetics and sedatives could be minimized. According to Bennett (1998) the recovery is unpredictable when injectable anesthetics are used and is often prolonged, requiring several days in some cases.

The temperature at which one maintains a patient is an important factor in the successful performance of reptilian anesthesia (Stirl and Bonath, 1994 and Preston *et al.*, 2010). Physiologically, reptiles have a low metabolic rate, slower respiratory rate and a

lower rate of oxygen consumption than mammals (Sladky and Mans, 2012). Recording of physiological parameters is an essentiality for monitoring the anesthetic depth. During the study, cloacal temperature of both snakes dropped down by 2 to 4 °F during the surgical plane of anesthesia as compared to the temperature before induction. However this was within the normal range.

Reptiles lack a diaphragm; they rely on the thoracic musculature for ventilation (Mosley, 2005). Because both inspiration and expiration are active processes, the respiratory depression associated with anesthesia may be more profound than that observed in species in which expiration is a passive process. Both peripheral receptor and centrally mediated control have been proposed. It seems more likely that there is an interaction between a central system, which generates the pattern of respiration, and afferent chemoreceptor input (Milsom, 1990 and Smatresk, 1990). Hence the profound fall in the respiratory rate as seen in both the snakes during anesthesia may be due to the depression of central and peripheral receptors and relaxation of the musculature.

Oxygen was used as the carrier gas for induction of anesthesia in both the snakes. The flow rate was set at 2 L/min of oxygen as recommended by Malley (1997) and Bennett (1998). Reptiles have a tendency to develop bradypnoea and apnoea when anaesthetized. Hence usage of oxygen as carrier gas will help in the maintenance of respiration (Sladky and Mans, 2012). However oxygen consumption in reptiles is very low. Perry (1989) opined that oxygen consumption is low in reptiles because of low metabolic rates and hence flow rates may be reduced considerably compared with mammalian settings. Hence 1 to 2 L/ min can be effectively used as a carrier gas for the inhalant anesthetic.

Unlike mammalian abscesses, reptile abscesses are well encapsulated with caseous and plug like purulent material inside. These capsules are nearly impenetrable to antibiotic therapy (Mader, 2006). Hence making the key to successful treatment of the reptilian abscesses is the complete removal of the abscess cavity and surrounding fibrous capsule (Mader, 2006). Alworth *et al.* (2011) also opined that in reptiles, instead of lancing the abscess, they have to be removed in toto. Abscess which appeared as capsule were removed as single mass altogether in both the snakes. Allworth *et al.* (2011) suggested that incised reptile skin has a tendency to invert for which everting suture patterns such as horizontal or vertical mattress are recommended to ensure opposition of tissue without future dysecdysis. The snakes in present study shed skin on 35<sup>th</sup> and 42<sup>nd</sup> day respectively without showing any signs of

dysecdysis at surgical site where horizontal mattress suturing pattern was used.

Objectives of housing in hospitals are to provide bare necessities such as cleanliness, warmth and security. Plastic designer containers showed good results as they were easy to sterilize, resistant to dampness and had prolonged self life. The same protocol for housing was suggested by Mader (2006). According to him materials used in reptile housing should be smooth, nonabrasive and nonabsorbent in nature.

## References

- Alworth, L.C., S.M. Hernandez and S.J. Divers (2011).** Laboratory reptile surgery: principles and techniques. *Journal of the American Association for Laboratory Animal Science*. 50(1): 11–26.
- Bennett, R.A. (1998).** Reptile Anesthesia. *Seminars in Avian and Exotic Pet Medicine*. 7(1): 30-40.
- Hoppmann, E. and H.W. Barron (2006).** Dermatology in reptiles. *Journal of Exotic Pet Medicine* 16(4): 210-224.
- Klingenberg R.J. (2011).** The Merck Manual for pet health. [http://www.merckmanuals.com/pethealth/exotic\\_pets/reptiles/disorders\\_and\\_diseases\\_of\\_reptiles.html](http://www.merckmanuals.com/pethealth/exotic_pets/reptiles/disorders_and_diseases_of_reptiles.html)>. On-line version accessed in July 2014.
- Mader, D.R. (1996).** Specific Diseases and Clinical Conditions. In: Mader, D. R (eds). *Reptile Medicine and Surgery* 1<sup>st</sup> edition. WB Saunders. Philadelphia.
- Mads, F.B. (2007).** Invertebrate, Fish, Amphibian, and Reptile Anesthesia, pp. 233-243. In: Gary, W., H. Darryl & C. Nigel (eds). *Zoo Animal & Wildlife-Immobilization and Anesthesia*. Blackwell publishing, Iowa.
- Malley, D. (1997).** Reptile anesthesia and the practicing veterinarian. *In Practice*. 19: 351-368
- Milsom, W.K. (1990).** Mechanoreceptor modulation of endogenous respiratory rhythms in vertebrates. *American Journal of Physiology*. 259: 898-910.
- Mosley, C.A. (2005).** Anesthesia and analgesia in reptiles. *Seminars in Avian and Exotic Pet Medicine* 14: 243-262
- Murphy, J.B. (1971).** A method for immobilising venomous snakes. *International Zoo Yearbook*, xi +233.
- Perry, S.F. (1989).** Structure and function of the reptilian respiratory system, pp. 193-236. In: Lenfant, C. & Wood, C.M (eds). *Comparative Pulmonary Physiology Current Concepts*, Marcel Dekker, New York.
- Preston, D.L., C.A.E. Mosley and R.T. Mason (2010).** Sources of variability in recovery time from methohexital sodium anesthesia in snakes. *Copeia*: 496-501.
- Read, M.R. (2004).** Evaluation of the use of anesthesia and analgesia in reptiles. *Journal of the American Veterinary Medical Association*. 224:547–552.
- Sladky, K.K. and C. Mans (2012).** Clinical anaesthesia in reptiles. *Journal of Exotic Pet Medicine*. 21: 17–31.
- Smatresk, N.J. (1990).** Chemoreceptor modulation of endogenous respiratory rhythms in vertebrates. *American Journal of Physiology*. 259: 887-897.
- Stirl, R. and K.H. Bonath (1994).** Cardiovascular, pulmonary and acid-base measurements in boa constrictors during tiletamine-zolazepam sedation. 5<sup>th</sup> International Congress of Veterinary Anesthesia. 55.
- Whitaker, R. and A. Captain (2004).** *Snakes of India: The Field Guide*. Draco Books. Chennai, India. pp 114.




Photo: N.S. Achyuthan