

A note on parasitic infections in Indian peacock

G. Ponnudurai*, K. Rajendran, N. Rani and T.J. Harikrishnan

Introduction

Among avian blood parasites, *Haemoproteus* species is cosmopolitan and has been reported to be infected in many avian species (Poharkar *et al.*, 2009). This parasite is transmitted from infected to healthy birds by arthropod vectors, including bird lice found in peacock. In this paper occurrence of *Haemoproteus* species and ectoparasites such as ticks and lice in a peacock is reported.

Materials and Methods

An ailing peacock was brought to the veterinary hospital complex of Veterinary College and Research Institute, Namakkal, Tamil Nadu by the forest personnel. The bird was unable to fly, showed visible signs of respiratory distress, anaemia and torticollis. In the head region, areas around the eyes and wattles were found studded with various stages of ticks. Upon combing through the feathers, movements of lice could be observed.

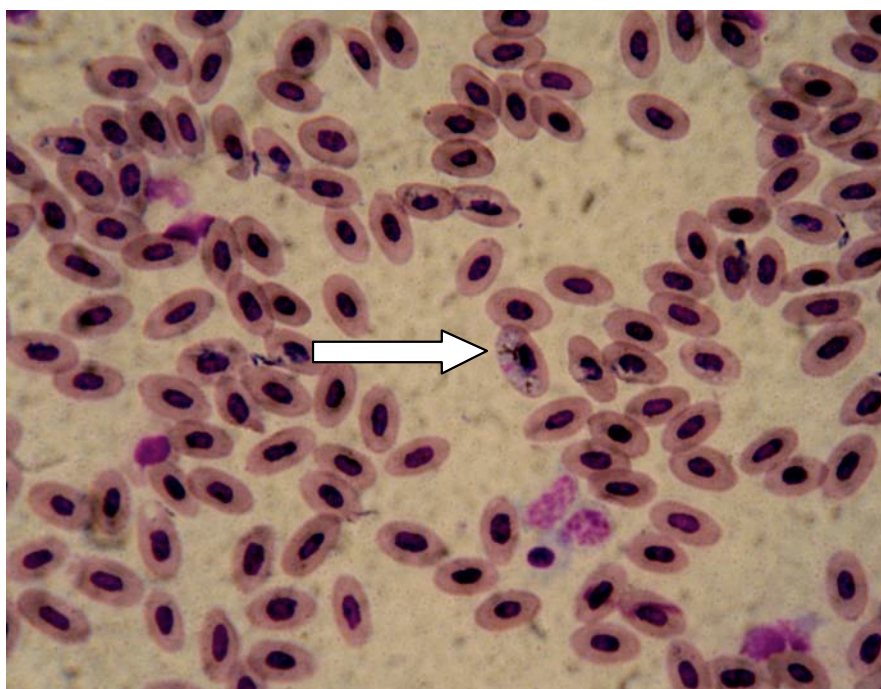


Fig. 1 Halter shaped - gamont of *Haemoproteus* spp. found in the RBC

Blood smears were prepared and stained with Giemsa stain. The stained smears were examined under 100x (oil immersion lens). The specific identity of the ticks that were collected from the peacock was determined as per the keys described by Soulsby (1982). The specific identity of the lice could not be determined.

Results and Discussion

In the present case, the clinical signs like increased body temperature, lateral recumbency, respiratory distress and inability to fly were observed. These findings corroborate with findings of Poharkar *et al.*, 2009 who observed all the above clinical signs in vultures that affected with malarial parasites *Haemoproteus* and *Plasmodium* spp. The ticks that were collected from the peacock were identified as *Haemaphysalis* spp.

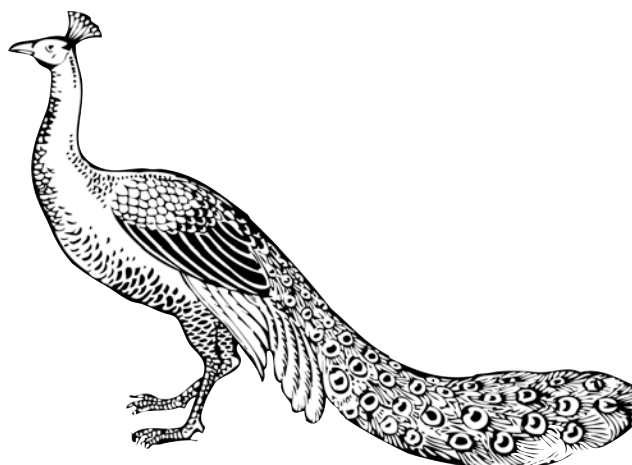
Examination of blood smears collected from the peacock revealed the presence of gametocytes of *Haemoproteus* parasites (Fig.1). As the bird was brought in a critical state, it died before antimalarial drug treatment could be started. This finding confirms the observation of Malkani, 1936 as he reported that *Haemoproteus* infection is highly fatal to Indian peacocks.

References

- Malkani, P.G., (1936). *Haemoproteus rileyi* (sp.nov) causing a fatal disease in Indian peacock. *Indian J. Vet.Sci.Anim.Husb.*, 6: 155-157.
- Poharkar, A., P.A. Reddy, V.A. Gadge, S. Kolte, N. Kurkure and S. Shivaji (2009). Is malaria the cause for decline in the wild population of the Indian white backed vulture. *Current Science* 96:553-558
- Soulsby, E.J.L., (1982). *Helminths, Arthropods and protozoa of Domesticated Animals*. 7th Edn, EIBS and Bailliere Tindall, London, 809pp.

Acknowledgement

The authors are grateful to the Dean, Veterinary College and Research Institute, Namakkal, for the facilities provided.



*Address for correspondence: Associate Professor, Department of Veterinary Parasitology, Veterinary College and Research Institute, Namakkal, Tamil Nadu – 637 002. Email: gponnu@rediffmail.com