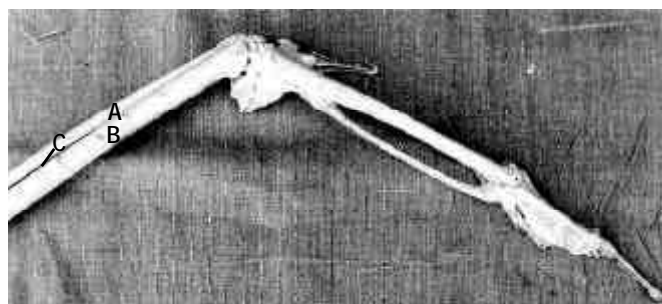


APPENDICULAR SKELETON OF THE FORE-ARM OF ADULT GREATER ADJUTANT STORK (*LEPTOPTILOS DUBIUS*)

Munmun Sarma¹, Arup Kalita² and Kushal Konwar Sarma³

¹ Assistant Professor, ² Research Associate, Department of Anatomy and Histology, ³ Associate Professor, Department of Surgery and Radiology,

College of Veterinary Science, Khanapara, Guwahati, Assam 781022, India.



A - radius; B - ulna; C - intersosseous space

Figure 1. Appendicular skeleton of forearm of adult Greater Adjutant Stork (*Leptoptilos dubius*)

A Greater Adjutant Stork (*Leptoptilos dubius*) was brought for treatment of a multiple fracture of the wing bone. On examination, it was found that the wing had to be amputated. The feathers, skin, and muscles of the amputated wing were removed, and the appendicular skeleton of the fore-arm was studied.

The ulna of the appendicular skeleton of the fore-arm was observed to be more massive than radius as stated by King and McLelland (1975). The two bones were almost equal in length - ulna being 38.6cm and radius 37.0cm. The diameter at the middle of the shaft of ulna was 2.27cm and 1.19cm in radius. Both the bones were separated from each other by a wider intersosseous space as detailed by Feduccia (1975).

The shaft of the ulna was almost cylindrical, bearing a series of well developed bony projections for attachment of secondary feathers of the wing on the outer surface as observed by King and McLelland (1975). There were altogether 13 bony prominences in the ulna of which the most proximal and distal ones were less prominent. The shaft of the radius was mediolaterally flattened.

Proximally, the ulna and radius articulated with the two condyles of the humerus, and distally with the carpals. On the proximal end of the radius, an articular facet was present, which articulated with the smaller humeral condyle, whereas, the ulna had a concave surface that articulated with the larger condyle of the humerus and a projection. The olecranon process of ulna projected from the proximal extremity as detailed by Nickel *et al.* (1977). Nutrient foramen was not observed in the entire length of ulna and was not in accordance with Feduccia (1975) who reported it to be present about mid-way of its length.

The distal extremity of the radius was observed to be consisting of a small facet for articulation with the ulna. The distal extremity

of ulna, on the other hand, consisted of two articular facets, one for articulation with the radio-carpal and the other with the ulno-carpal bones.

References

- Feduccia, A. (1975).** Aves Osteology, pp.1796-1798. In: Getty, R. (Editor). Sisson and Grossman's *The Anatomy of Domestic Animals*, 5th edition, W.B. Saunders Co., Philadelphia.
- King, A.S. and J. McLelland (1975).** Skeleto muscular system, pp.15-29. In: *Outlines of Avian Anatomy*. The Macmillan Publishing Company Inc., New York.
- Nickel, R., A. Schummer and E. Seiferle (1977).** Skeleton of the forelimb, pp.13-15. In: *Anatomy of Domestic Birds*. Verlag Paul Parey, Berlin, Hamburg.

Received 4 October 2001

Finally accepted 2 September 2002